

Clinical Cancer Research

Overexpression of Cellular Iron Import Proteins Is Associated with Malignant Progression of Esophageal Adenocarcinoma

Jessica Boult, Keith Roberts, Matthew J. Brookes, et al.

Clin Cancer Res 2008;14:379-387. Published online January 25, 2008.

Updated Version Access the most recent version of this article at:
doi:[10.1158/1078-0432.CCR-07-1054](https://doi.org/10.1158/1078-0432.CCR-07-1054)

Cited Articles This article cites 37 articles, 17 of which you can access for free at:
<http://clincancerres.aacrjournals.org/content/14/2/379.full.html#ref-list-1>

Citing Articles This article has been cited by 3 HighWire-hosted articles. Access the articles at:
<http://clincancerres.aacrjournals.org/content/14/2/379.full.html#related-urls>

E-mail alerts [Sign up to receive free email-alerts](#) related to this article or journal.

Reprints and Subscriptions To order reprints of this article or to subscribe to the journal, contact the AACR Publications Department at pubs@aacr.org.

Permissions To request permission to re-use all or part of this article, contact the AACR Publications Department at permissions@aacr.org.

Overexpression of Cellular Iron Import Proteins Is Associated with Malignant Progression of Esophageal Adenocarcinoma

Jessica Boulton,¹ Keith Roberts,¹ Matthew J. Brookes,¹ Sharon Hughes,¹ Jonathan P. Bury,³ Simon S. Cross,³ Gregory J. Anderson,⁴ Robert Spychal,² Tariq Iqbal,¹ and Chris Tselepis¹

Abstract Purpose: There is growing evidence that iron is important in esophageal adenocarcinoma, a cancer whose incidence is rising faster than any other in the Western world. However, how iron mediates carcinogenesis at the molecular level remains unclear. In this study, we investigated the expression of iron transport proteins involved in cellular iron import, export, and storage in the premalignant lesion Barrett's metaplasia and esophageal adenocarcinoma.

Experimental Design: Perl's staining was used to examine iron deposition in tissue. mRNA expression in samples of Barrett's metaplasia matched with esophageal adenocarcinoma and samples of Barrett's metaplasia without evidence of adenocarcinoma were examined by real-time PCR. Semiquantitative immunohistochemistry was used to examine cellular localization and protein levels. The effect of iron loading on cellular proliferation and iron transporter expression was determined in esophageal cell lines OE33 and SEG-1 using a bromodeoxyuridine assay and real-time PCR, respectively.

Results: In the progression of Barrett's metaplasia to adenocarcinoma, there was overexpression of divalent metal transporter 1 (DMT1), transferrin receptor 1, duodenal cytochrome b, ferroportin, and H-ferritin, and these changes were associated with increased iron deposition. Overexpression of DMT1 was further associated with metastatic adenocarcinoma. Iron loading OE33 and SEG-1 cells caused increased cellular proliferation, which was associated with increased H-ferritin and decreased transferrin receptor 1 and DMT1 expression.

Conclusions: Progression to adenocarcinoma is associated with increased expression of iron import proteins. These events culminate in increased intracellular iron and cellular proliferation. This may represent a novel mechanism of esophageal carcinogenesis.

Esophageal adenocarcinoma is a cancer whose incidence has seen an unprecedented increase in the last 30 years with no apparent evidence of a downturn (1, 2). The prognosis for patients with esophageal adenocarcinoma remains extremely poor with 5-year survival rates approximating 10% in most Western populations (3). The strongest known risk factor is

Barrett's metaplasia, a condition characterized by the replacement of native squamous esophageal mucosa with a columnar epithelium, probably as a consequence of prolonged reflux of gastric contents into the lower esophagus (1, 4). It is estimated that Barrett's metaplasia increases the risk of developing esophageal adenocarcinoma approximately 30- to 125-fold (5, 6).

In addition to the plethora of proteins implicated in the malignant progression of Barrett's metaplasia to adenocarcinoma, including c-MYC (7), there is evidence suggesting that iron is important in the development of esophageal cancer (8–14). The involvement of iron in esophageal carcinogenesis is exemplified by a series of studies using an animal model in which rats underwent an esophagoduodenal anastomosis to mimic reflux (10–12). Rates of esophageal adenocarcinoma 30 weeks after surgery were ~10-fold higher in animals supplemented with iron than in nonsupplemented animals. The cellular role of iron in carcinogenesis has been attributed to its potential to induce reactive oxygen species, DNA adducts, and cellular proliferation and repress cell adhesion (15–18).

Iron is principally absorbed in the duodenum where dietary ferric iron is reduced and transported into the enterocyte by the proteins duodenal cytochrome b (DCYTB) and divalent metal transporter 1 (DMT1), respectively (19–21). The iron can then be either stored in an inert form bound to ferritin (22), used by the cell, or exported from the enterocyte via a pathway that

Authors' Affiliations: ¹Cancer Research UK Institute for Cancer Studies, University of Birmingham; ²Sandwell and West Birmingham Hospitals NHS Trust, Birmingham, United Kingdom; ³Academic Unit of Pathology, University of Sheffield Medical School, Sheffield, United Kingdom; and ⁴Iron Metabolism Laboratory, Queensland Institute of Medical Research, PO Royal Brisbane Hospital, Brisbane, Queensland, Australia

Received 5/3/07; revised 10/11/07; accepted 10/11/07.

Grant support: City Hospital Trust Fund and the University of Birmingham Scientific project grant. The tissue microarray construction was supported by a grant from the Special Trustees of Sheffield Teaching Hospitals NHS Foundation Trusts.

The costs of publication of this article were defrayed in part by the payment of page charges. This article must therefore be hereby marked *advertisement* in accordance with 18 U.S.C. Section 1734 solely to indicate this fact.

Note: T. Iqbal and C. Tselepis contributed equally to this work.

Requests for reprints: Chris Tselepis, Cancer Research UK Institute for Cancer Studies, University of Birmingham, Vincent Drive, Birmingham B15 2TH, United Kingdom. Phone: 44-121-414-2972; Fax: 44-121-627-2384; E-mail: c.tselepis@bham.ac.uk.

© 2008 American Association for Cancer Research.
doi:10.1158/1078-0432.CCR-07-1054

requires the ferroxidase hephaestin (23, 24) and the basolateral iron transporter ferroportin (25). Iron is transported in the serum bound to transferrin, which interacts with transferrin receptor 1 (TfR1) on the plasma membrane of cells that take up iron. The iron/transferrin complex is internalized by receptor-mediated endocytosis and iron released (26). In esophageal keratinocytes, the main route of iron acquisition is likely to be through the transferrin receptor-mediated endocytic pathway. Luminal iron absorption in the esophagus is highly unlikely.

A role for iron in carcinogenesis is further strengthened by our own studies showing that in the human colonic adenoma to carcinoma sequence there is a modulation in the expression of iron transport proteins, particularly an overexpression of DCYTB, DMT1, and TfR1 and a reduction in hephaestin (15). These changes culminate in increased intracellular iron import and reduced iron efflux leading to increased intracellular iron, which we believe is crucial in driving Wnt signaling, a common oncogenic signaling pathway (27).

Our hypothesis is that the modulation of iron transport proteins, culminating in cellular iron accumulation, represents a mechanism of carcinogenesis central to all cancers. Thus, the primary aim of this study was to characterize the expression of the iron import (DCYTB, DMT1, and TfR1), export (ferroportin and hephaestin), and storage (H-ferritin) proteins in normal esophagus, Barrett's metaplasia, and esophageal adenocarcinoma and to further determine the effect of increased intracellular iron on esophageal cellular proliferation and the expression of iron transport proteins.

Materials and Methods

Ethics

This work has been carried out in accordance with the Declaration of Helsinki (2000) of the World Medical Association. Ethical approval for this study was approved by University Hospital Birmingham Trust (LREC 2002/166). All patients provided informed written consent. Immunohistochemical studies using the tissue microarrays were approved by the South Sheffield Research Ethics Committee (02/155).

Patient tissue

Esophageal adenocarcinoma resection specimens. Samples of esophageal adenocarcinoma ($n = 29$), some of which were matched with Barrett's metaplasia ($n = 11$) from the same resection specimen, were collected during surgery and each tissue specimen was divided in two for RNA extraction and pathologic confirmation.

Endoscopic specimens. Samples of long-segment (≥ 3 cm) Barrett's metaplasia ($n = 13$), defined as columnar mucosa with intestinal-type goblet cells, with matched normal gastric fundal mucosa and esophageal squamous mucosa from the same patient were collected during endoscopy. Each tissue specimen was divided in two for RNA extraction and immunohistochemistry. Any patients with Barrett's metaplasia with evidence of dysplasia or adenocarcinoma were excluded from this study.

Archived tissue. Paraffin sections of normal esophagus ($n = 10$), Barrett's metaplasia from patients with no evidence of esophageal dysplasia or adenocarcinoma (BM-ve; $n = 20$), Barrett's metaplasia with adenocarcinoma in the same section (BM+ve; $n = 20$), Barrett's with low-grade dysplasia ($n = 10$), Barrett's with high-grade dysplasia ($n = 20$), and esophageal adenocarcinoma ($n = 20$) were identified within the archived tissue bank, Department of Pathology, Queen Elizabeth's Hospital Birmingham, and processed for immunohistochemistry.

Real-time PCR

Real-time PCRs were done using 18S rRNA as an internal standard (PE Biosystems, Roche) and primers to *DMT1* [iron response element (IRE)-containing isoform], *TfR1*, *DCYTB*, *ferroportin*, *hephaestin*, *H-ferritin*, and *MYC* as previously described (7, 15). All analyses were done on the same pool of cDNA samples.

Immunohistochemistry

Immunohistochemistry was done as previously described (15) using microwave antigen retrieval and rabbit polyclonal antibodies to (a) DCYTB (1:200, clone 834; a kind gift from Prof. A. McKie), (b) DMT1 (1:3,000; ADI), (c) ferroportin (1:200, clone 3566; a kind gift from Prof. A. McKie), (d) H-ferritin (1:1,000, F-5012; Sigma), and (e) hephaestin (1:50, HEPH11-A; ADI) or a mouse monoclonal antibody to TfR1 (1:40, clone 10F11; Novocastra). Small bowel mucosa was included as a positive control, and omission of primary antibody and the use of rabbit serum alone and isotype controls were all used as negative controls. In addition, cellular iron localization was assessed by 3,3'-diaminobenzidine-enhanced Prussian blue staining as previously described (15). The slides were scored by a previously described method for intensity of staining and percentage of epithelial cell staining (28). All sections were scored independently by three observers (S.H., K.R., and C.T.).

Tissue microarrays

A separate set of esophageal carcinoma specimens ($n = 76$) collected between 2000 and 2005, for which clinicopathologic data were available, was used to evaluate the association between iron transporter levels and prognostic factors. The prognostic factors included T stage, differentiation status, vascular invasion, and nodal involvement. Each tumor is represented on the microarray in triplicate to provide representative sampling of the source tissue. Immunohistochemistry and scoring were done as described above.

Western blotting

Western blotting was done as described previously with antibodies to either ferroportin (1:1,000) or H-ferritin (1:2,500; ref. 15). A mouse monoclonal antibody to cytokeratin 19 (1:2,000, clone A53-B/A2.26; Merck Chemicals Ltd.) was used for normalization of epithelial protein

Table 1. Analysis of mRNAs encoding iron transport proteins in Barrett's metaplasia and adenocarcinoma

Gene	Mean fold change in mRNA expression		
	BM-ve vs G	BM-ve vs S	ADC vs BM+ve
<i>TfR1</i>	1.87	1.75*	11.5*
<i>DMT1</i> (IRE+ve)	1.79*	1.71*	6.51*
<i>DCYTB</i>	1.09	2.91*	4.05*
<i>Ferroportin</i>	2.95	6.91*	14.8*
<i>Hephaestin</i>	1.96	14.95*	1.20
<i>H-ferritin</i>	2.37	3.97*	2.98*

NOTE: Mean fold changes in mRNA levels of *TfR1*, *DMT1*, *DCYTB*, *ferroportin*, *hephaestin*, and *H-ferritin* in samples of (a) intestinal-type Barrett's metaplasia (with no evidence of associated adenocarcinoma) compared with matched gastric mucosa, (b) intestinal-type Barrett's metaplasia compared with matched squamous esophageal mucosa, and (c) esophageal adenocarcinoma matched with Barrett's metaplasia obtained from the same resection specimen as the comparative control were determined.

Abbreviations: ADC, adenocarcinoma; G, gastric mucosa; S, normal squamous esophagus.

*Significant differences in mean mRNA expression between the two mucosae ($P < 0.05$).

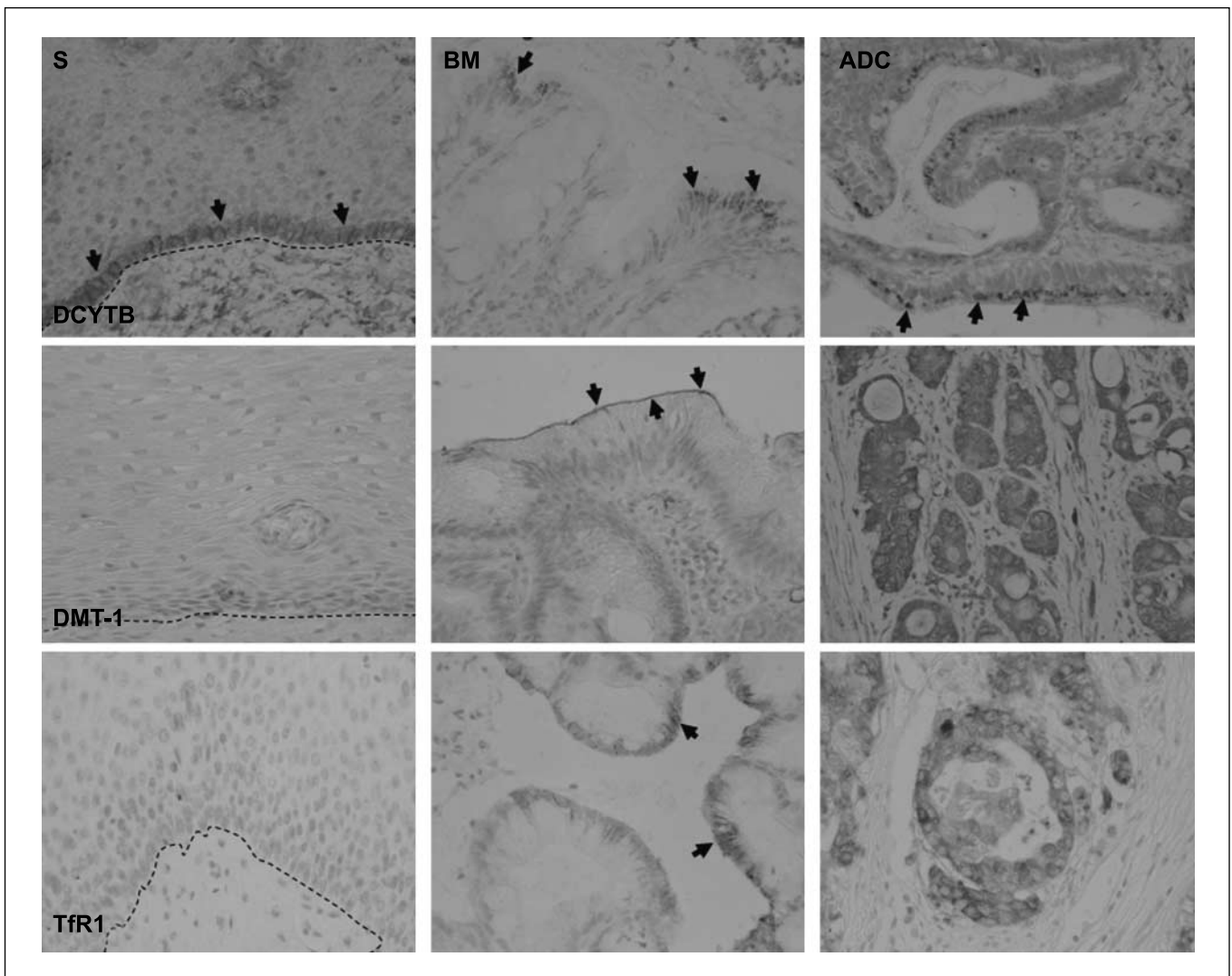


Fig. 1. Immunolocalization of proteins implicated in cellular iron import in normal esophagus, intestinal-type Barrett's metaplasia, and esophageal adenocarcinoma. Paraffin sections of normal squamous esophagus (S), Barrett's metaplasia (BM), and esophageal adenocarcinoma (ADC) were subjected to immunohistochemistry using antibodies to DCYTB, DMT1, and TfR1. Dashed line, basal squamous layer-connective tissue interface; arrows, areas of positivity. Original magnification, $\times 40$.

loading. Immunoreactive bands were then subjected to densitometry using NIH Image 1.62 software.

Cell culture

Cell lines derived from esophageal adenocarcinomas [OE33 (29) and SEG-1 (30)] were routinely cultured in DMEM (Life Technologies) with 10% FCS supplemented with 100 units/mL penicillin and 0.1 mg/mL streptomycin. On reaching 70% confluence, lines were challenged with either growth medium alone (control) or iron loading medium (growth medium supplemented with 100 $\mu\text{mol/L}$ FeSO_4 and 10 $\mu\text{mol/L}$ sodium ascorbate) for between 1 and 24 h. FeSO_4 (100 $\mu\text{mol/L}$) was chosen as this source of iron and concentration has been used in previous studies (15, 27). Furthermore, this concentration of iron was shown to be optimal for esophageal cellular proliferation (data not shown). At the end of the time period, cells were used for intracellular iron determination, RNA extraction, or cell proliferation assays. All experiments were done in triplicate on three separate occasions.

Bromodeoxyuridine incorporation assay

A colorimetric cell proliferation ELISA was done according to the manufacturer's instructions (Roche Applied Science). Briefly, cells were labeled with bromodeoxyuridine followed by fixation and incubation

with anti-bromodeoxyuridine peroxidase, and the immune complex was then detected using a 3,3',5,5'-tetramethylbenzidine substrate with the reaction product assessed at 370 nm.

Ferrozine assay

Nonhaem iron was assayed as previously described (15) and cellular iron content was expressed as nmoles of iron per mg protein. Protein concentrations were assessed by the bicinchoninic acid protein assay according to the manufacturer's instructions (Pierce).

Statistics

All data are presented as mean \pm 1 SE. Statistical significance was calculated using Mann-Whitney tests for analysis of immunohistochemical staining, paired *t* tests for mRNA analysis where multiple samples were obtained from individual patients, and unpaired Student's *t* tests for analysis of the *in vitro* experiments. To assess the association between *c-MYC* and iron transport proteins, linear regression analysis was done on log-transformed mRNA fold change values, and the R^2 value was determined to show the extent to which expression of *TfR1* and *H-ferritin* was correlated to *MYC* (31). A Bonferroni adjustment was applied to *P* values attained from multiple comparisons during the analysis of prognostic factors (32). In

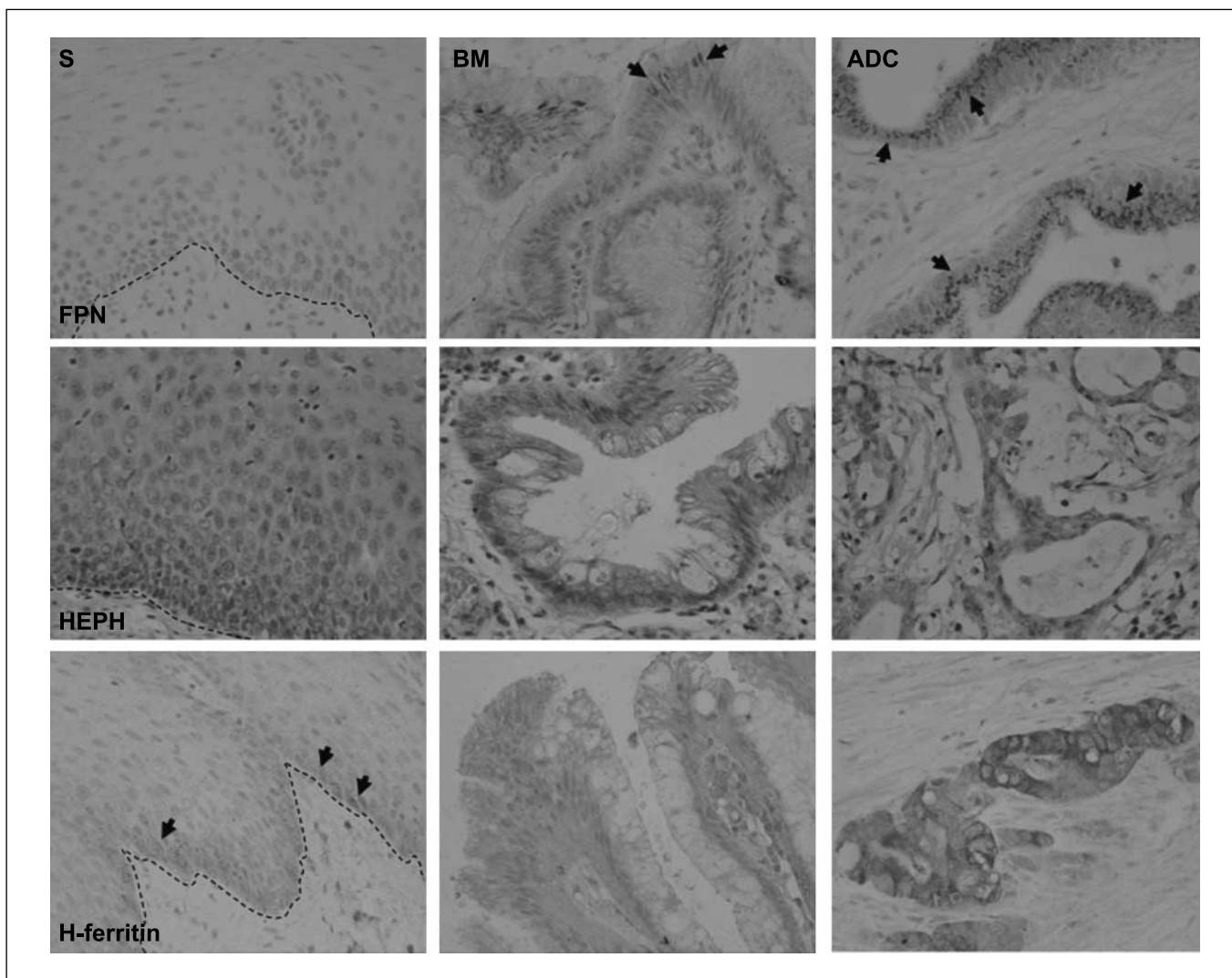


Fig. 2. Immunolocalization of proteins implicated in cellular iron export and storage in normal esophagus, Barrett's metaplasia, and esophageal adenocarcinoma. Paraffin sections of normal squamous esophagus, Barrett's metaplasia, and esophageal adenocarcinoma were subjected to immunohistochemistry using antibodies to ferroportin (FPN), hephaestin (HEPH), and H-ferritin. Dashed line, basal squamous layer-connective tissue interface; arrows, areas of positivity. Original magnification, $\times 40$.

univariate analyses, significance was accepted at $P \leq 0.05$ following Bonferroni adjustment, and $P \leq 0.0083$ was considered significant. All analyses were done using Statistical Package for the Social Sciences version 10.0 (SPSS, Inc.).

Results

mRNA expression of iron metabolism molecules in Barrett's metaplasia and esophageal adenocarcinoma specimens

The expression of mRNAs encoding TfR1, DMT1, DCYTB, ferroportin, hephaestin, and H-ferritin in benign Barrett's metaplasia (BM-ve) was initially assessed and compared with internal matched gastric and esophageal squamous control tissue. Relative to squamous mucosa, the mRNAs encoding all iron metabolism proteins studied were increased in Barrett's metaplasia (Table 1). When comparing intestinal Barrett's metaplasia with matched gastric mucosa, only *DMT1* was significantly altered (Table 1). To determine if there was any further change in these transcripts in esophageal adenocarcinoma, matched internal Barrett's metaplasia (BM+ve) obtained

from the same resection specimen was used as the comparative control. We show that the expression levels of all transcripts are statistically higher in esophageal adenocarcinoma than the associated Barrett's metaplasia, with the exception of *hephaestin* (Table 1). In terms of transcript levels in adenocarcinoma, the highest to lowest were *H-ferritin* ($dCt = 9.08 \pm 0.13$) > *ferroportin* ($dCt = 14.06 \pm 0.31$) > *TfR1* ($dCt = 15.18 \pm 0.19$) > *DCYTB* ($dCt = 16.28 \pm 0.31$) > *hephaestin* ($dCt = 16.35 \pm 0.32$), with the least expressed being *DMT1* ($dCt = 17.46 \pm 0.25$).

Because we had previously shown that the oncogene *c-MYC* was overexpressed in esophageal adenocarcinoma and that previous reports have suggested that *c-MYC* can induce *TfR1* and repress *H-ferritin*, we chose to examine the transcriptional relationship between *MYC* and *TfR1*, and *MYC* and *H-ferritin* expression in all the esophageal adenocarcinoma samples ($n = 29$). Using linear regression analysis on log-transformed mRNA expression values, we were able to show that *MYC* mRNA expression in esophageal adenocarcinoma specimens was positively associated with *TfR1* ($R^2 = 0.203$; $P = 0.014$) and also with *H-ferritin* mRNA expression ($R^2 = 0.144$; $P = 0.042$).

Table 2. Semiquantitative analysis of iron transport proteins in the malignant progression of Barrett's metaplasia to adenocarcinoma

Protein	Mean fold change in protein expression		
	ADC vs BM+ve	HGD vs BM+ve	LGD vs BM+ve
TfR1	5.07*	5.43*	0.98
DMT1 (IRE+ve)	7.06*	1.72	1.67
DCYTB	7.72*	1.65*	0.54
Ferroportin	2.80*	1.08	1.17
Hephaestin	1.21	1.53	0.91
H-ferritin	3.38*	1.67	0.15

NOTE: Immunohistochemistry for TfR1, DMT1, DCYTB, ferroportin, hephaestin, and H-ferritin was done on archived paraffin tissue specimens of (a) intestinal-type Barrett's metaplasia associated with adenocarcinoma ($n = 20$), (b) Barrett's metaplasia with low-grade dysplasia ($n = 10$), (c) Barrett's metaplasia with high-grade dysplasia ($n = 20$), and (d) esophageal adenocarcinoma ($n = 20$). All slides were quantitated as described in Materials and Methods. The mean staining scores were calculated for each type of mucosa and the mean fold change in protein expression was calculated. Abbreviations: LGD, low-grade dysplasia; HGD, high-grade dysplasia.

*Significant differences between the two groups being compared ($P < 0.05$).

However, there was no association between *MYC* and *TfR1* or between *MYC* and *H-ferritin* in Barrett's metaplasia specimens ($n = 24$).

Immunolocalization of iron metabolism proteins in archived tissue

To complement the mRNA analyses, we did semiquantitative immunohistochemistry on archived paraffin tissue specimens from patients with a range of esophageal pathologies (Figs. 1 and 2). In addition to cellular localization being determined, all staining was scored (Table 2) as described above.

Iron import proteins. In normal esophagus, DCYTB was strongly expressed in the basal layer of the stratified epithelium, with immunoreactivity in both the cytoplasm and on the plasma membrane. In Barrett's metaplasia, DCYTB immunore-

activity was predominantly localized on the villous tips with decreasing reactivity in the deeper lying crypts. Immunoreactivity was predominantly supranuclear and vesicular. This pattern of cellular localization was retained in low- and high-grade dysplasia and in esophageal adenocarcinoma (Fig. 1). However, there was significantly higher DCYTB immunoreactivity in high-grade dysplastic Barrett's metaplasia and also in adenocarcinoma compared with nondysplastic Barrett's metaplasia ($P = 0.045$ and 0.0001 , respectively; Table 2).

No discernible DMT1 immunoreactivity was observed in normal esophageal epithelium unlike in Barrett's metaplasia where staining was evident on the apical surface epithelium. However, no immunoreactivity was observed in the deeper lying crypts. In the majority of columnar cells with low- and high-grade dysplasia, there was cytoplasmic staining, which became more widespread in adenocarcinoma (Fig. 1). Semiquantitative analysis showed a statistical increase in DMT1 immunoreactivity in esophageal adenocarcinoma compared with nondysplastic Barrett's metaplasia ($P = 0.001$; Table 2).

TfR1, like DMT1, was not detected in normal esophagus. In Barrett's metaplasia, there was lateral membranous immunoreactivity in all columnar cells, whereas in high-grade dysplastic Barrett's metaplasia and in adenocarcinoma there was an abundance of both membranous and cytoplasmic immunoreactivity (Fig. 1). Semiquantitative analysis revealed that there was significantly higher TfR1 immunoreactivity in high-grade dysplastic Barrett's metaplasia and also in adenocarcinoma compared with nondysplastic Barrett's metaplasia ($P = 0.0001$ and 0.0001 , respectively; Table 2).

Iron export and storage proteins. Neither ferroportin nor hephaestin was detected in normal squamous mucosa but there was evidence of immunoreactivity for both proteins in Barrett's metaplasia. Localization of ferroportin was mostly supranuclear on the surface epithelium with diminishing reactivity down into the crypts. Hephaestin was localized in a diffuse cytoplasmic manner throughout all columnar cells with immunoreactivity more intense toward the basal pole of the columnar cells. In adenocarcinoma, whereas there was an abundance of discrete supranuclear and vesicular ferroportin immunoreactivity, there was only weak diffuse immunoreactivity for hephaestin (Fig. 2). Semiquantitative analysis showed that ferroportin was overexpressed in adenocarcinoma compared with nondysplastic

Table 3. Semiquantitative analysis of immunoreactivity of iron transport proteins in an esophageal adenocarcinoma tissue array

Protein	T stage		Differentiation		Vascular invasion		Nodal involvement	
	T2	T3	Well moderate	Poor	Negative	Positive	Negative	Positive
DMT1	2.5	3.02	3.02	2.38	2.77	3.24	1.93	3.34*
DCYTB	4.97	4.44	4.85	4.43	4.78	4.87	4.9	4.79
TfR1	5.96	9.36	9.04	7.4	7.84	9.00	4.56	9.88
H-ferritin	1.65	2.49	2.75	1.66	2.43	2.17	1.52	2.69
Ferroportin	2.99	2.6	2.66	2.33	2.7	2.38	2.33	2.71
Hephaestin	0.14	0.28	0.3	0.11	0.24	0.16	0.35	0.15

NOTE: Esophageal adenocarcinomas ($n = 76$) for which complete clinical data were available (T stage, differentiation, extent of vascular invasion, and nodal involvement) were used to evaluate the association between iron transporter levels and these prognostic factors. Immunohistochemistry was done with antibodies to DCYTB, DMT1, ferroportin, H-ferritin, TfR1, and hephaestin. Staining scores were calculated as described in Materials and Methods. Increased expression of DMT1 was associated with positive nodal involvement.

*Following application of the Bonferroni adjustment for multiple comparisons, differences in staining intensity between tumors with or without the specified characteristic were considered significant at $P \leq 0.0083$.

Barrett's metaplasia ($P = 0.0002$), whereas hephaestin expression showed no statistical difference in expression when compared with nondysplastic Barrett's metaplasia.

The storage protein H-ferritin was expressed in normal squamous esophagus in a distribution similar to that of DCYTB. Immunoreactivity was mostly confined to the basal layer and was predominantly cytoplasmic in all columnar cells. In nondysplastic and dysplastic Barrett's metaplasia, weak diffuse immunoreactivity was observed in all cellular compartments, whereas in adenocarcinoma there was an abundance of cytoplasmic immunoreactivity (Fig. 2). Semiquantitative analysis showed that H-ferritin was overexpressed in adenocarcinoma compared with nondysplastic Barrett's metaplasia ($P = 0.04$; Table 2).

Thus, in the progression from normal esophagus through Barrett's metaplasia to adenocarcinoma, there is an overexpression of iron import proteins (DCYTB, DMT1, and TfR1), iron export protein (ferroportin), and iron storage protein (H-ferritin). However, there was no alteration in hephaestin expression.

Tissue microarray. We further sought to determine whether changes in protein expression were associated with prognostic factors, such as stage of disease and nodal involvement, by using a tissue array of esophageal adenocarcinomas with known outcome (Table 3). The tissue microarray analysis showed no significant changes in staining intensity for any of

the iron transport proteins analyzed with respect to T stage, tumor differentiation status, presence of vascular invasion, age, or gender. However, DMT1 expression was significantly associated with lymph node involvement ($P = 0.0068$).

Enhanced Perls' Prussian blue staining. To determine whether these changes in expression and localization of the iron metabolism proteins were associated with increased intracellular iron, we did enhanced Perls' Prussian blue staining on tissue sections. In normal squamous esophagus ($n = 20$), there was no discernible staining other than in occasional basal keratinocytes, whereas in Barrett's metaplasia specimens ($n = 20$) there was evidence of diffuse cytoplasmic staining in approximately half of the specimens examined. In the majority of esophageal adenocarcinoma specimens ($n = 20$), there were discrete areas of iron staining that seemed to be both nuclear and cytoplasmic in localization (Fig. 3).

The effect of increased intracellular iron levels on cellular proliferation. To determine the effect of iron loading on cell behavior, we experimentally iron loaded the esophageal adenocarcinoma-derived cell lines OE33 and SEG-1. Cells were exposed to iron for 24 h and cellular iron content and cellular proliferation were assessed using standard ferrozine and bromodeoxyuridine assays, respectively (Fig. 4A and B). Following 24 h of culture under iron-loading conditions, both OE33 and SEG-1 showed significantly increased intracellular iron ($P = 0.001$; mean, 0.45 and 0.20 nmol/mg protein,

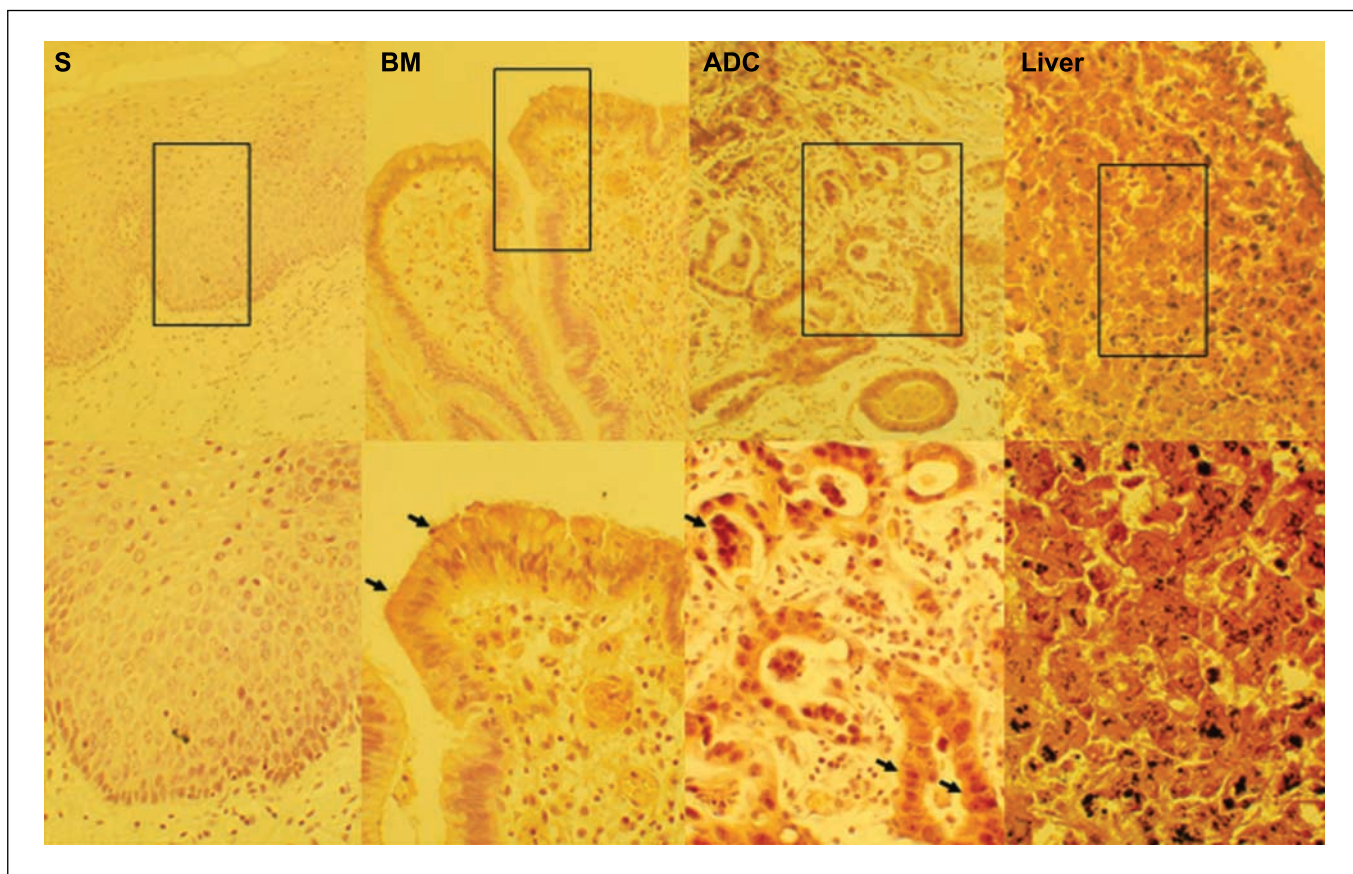


Fig. 3. Elevated 3,3'-diaminobenzidine – enhanced Prussian blue staining in esophageal adenocarcinoma. Sections of normal squamous esophagus, intestinal-type Barrett's metaplasia, and esophageal adenocarcinoma were subjected to 3,3'-diaminobenzidine – enhanced Perls' Prussian blue staining. A section of liver from a patient with hereditary hemochromatosis was used as a positive control. Original magnifications, $\times 20$ and $\times 40$.

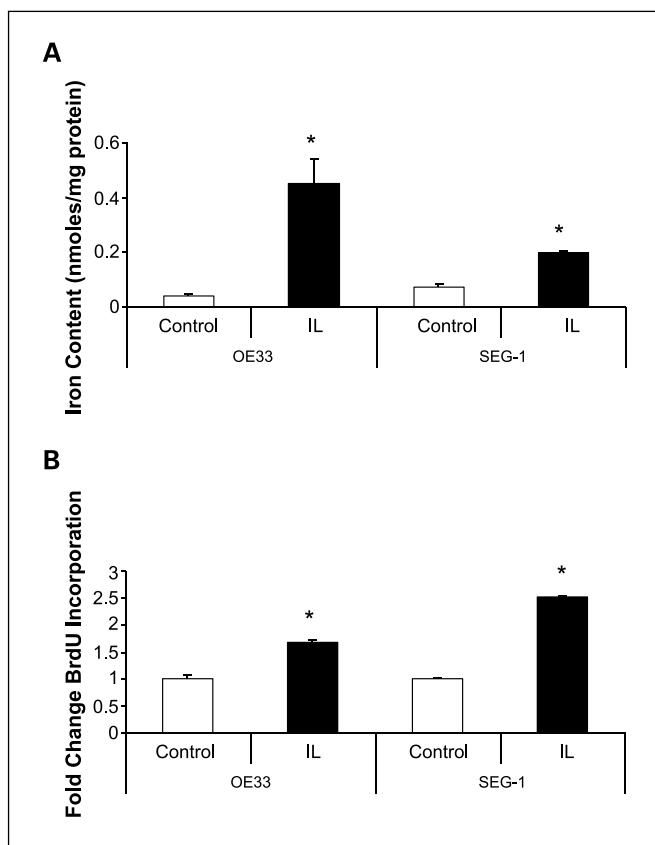


Fig. 4. Iron loading of OE33 and SEG-1 cells causes increased proliferation. OE33 and SEG-1 cells were cultured either in control medium or medium supplemented with 100 $\mu\text{mol/L}$ FeSO_4 for 24 h. *A*, cellular iron accumulation following iron loading (IL) was verified by ferrozine assay. *B*, the effect of iron loading on cellular proliferation was assessed by a bromodeoxyuridine (BrdU) assay. Columns, mean of three independent experiments, each done in triplicate; bars, SE. *, $P < 0.05$.

respectively; Fig. 4A). This increased intracellular iron was associated with a significant increase in cellular proliferation compared with control non-iron-loaded OE33 and SEG-1 cells ($P = 0.001$; Fig. 4B).

The effect of increased intracellular iron levels on iron transporter expression. The effect of increased cellular iron on the mRNAs encoding the iron metabolism proteins was also examined in esophageal adenocarcinoma cell lines (Fig. 5). In both OE33 and SEG-1 cells, the profile of transcript expression in untreated cells was comparable with that observed in adenocarcinoma tissue, with the most highly expressed transcript being *H-ferritin*. Iron loading both OE33 and SEG-1 cells resulted in significant reductions in both *TfR1* and *DMT1* mRNA expression (Fig. 5A) as expected because both mRNAs contain IREs within their 3' untranslated regions (33, 34). No change in *DCYTB*, *DMT1*, *hephaestin*, or *H-ferritin* mRNA levels was observed (Fig. 5A and B). At the protein level, there was a significant increase in H-ferritin expression following iron loading in both cell lines (Fig. 6A). Interestingly, ferroportin was also significantly repressed in SEG-1 cells (Fig. 6B).

Discussion

In this study, we investigated, for the first time, the expression of iron metabolism proteins in the evolution of

esophageal adenocarcinoma. In the examination of Barrett's metaplastic tissue, it was evident that there was expression of these iron metabolism proteins consistent with an intestine-like phenotype. When comparing Barrett's metaplasia with esophageal squamous control, significant expression changes in all the iron metabolism proteins were observed, which we believe reflect the fact that we are comparing different types of mucosa, intestinal columnar mucosa with a stratified squamous mucosa.

During the progression from Barrett's metaplasia to adenocarcinoma, we showed that components of the main cellular iron import machinery (*TfR1*, *DMT1*, and *DCYTB*) were overexpressed, as was the iron storage protein H-ferritin. Surprisingly, the major iron export protein ferroportin was also overexpressed under these conditions, although it seemed to be cytoplasmic in localization, suggesting a lack of functionality. These data are comparable with our previous findings in colorectal carcinogenesis (15).

Using a semiquantitative method, we further showed that these changes in iron transport proteins were not just evident in late-stage disease but that two of the proteins, *TfR1* and *DCYTB*, were induced in the transition from low- to high-grade Barrett's dysplasia. Akin to our previous data in colon carcinogenesis, *DMT1* overexpression was associated with more aggressive disease, as shown by the correlation of *DMT1* expression and

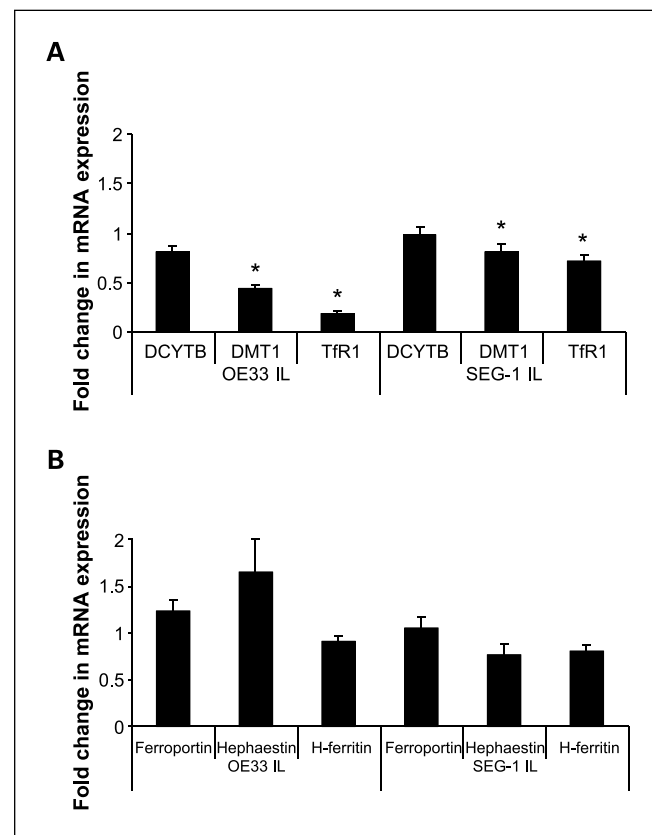


Fig. 5. Iron loading modulates iron transporter mRNA expression. To determine whether iron loading modulated the expression of mRNAs encoding proteins implicated in cellular iron import (*DCYTB*, *DMT1*, and *TfR1*; *A*) or cellular iron efflux and storage (ferroportin, hephaestin, and H-ferritin; *B*), control and 24-h iron-loaded OE33 and SEG-1 cells were assessed by real-time PCR. Relative gene expression is expressed as a ratio of the control value normalized to 1.0. Columns, mean of three independent experiments; bars, SE. *, $P < 0.05$.

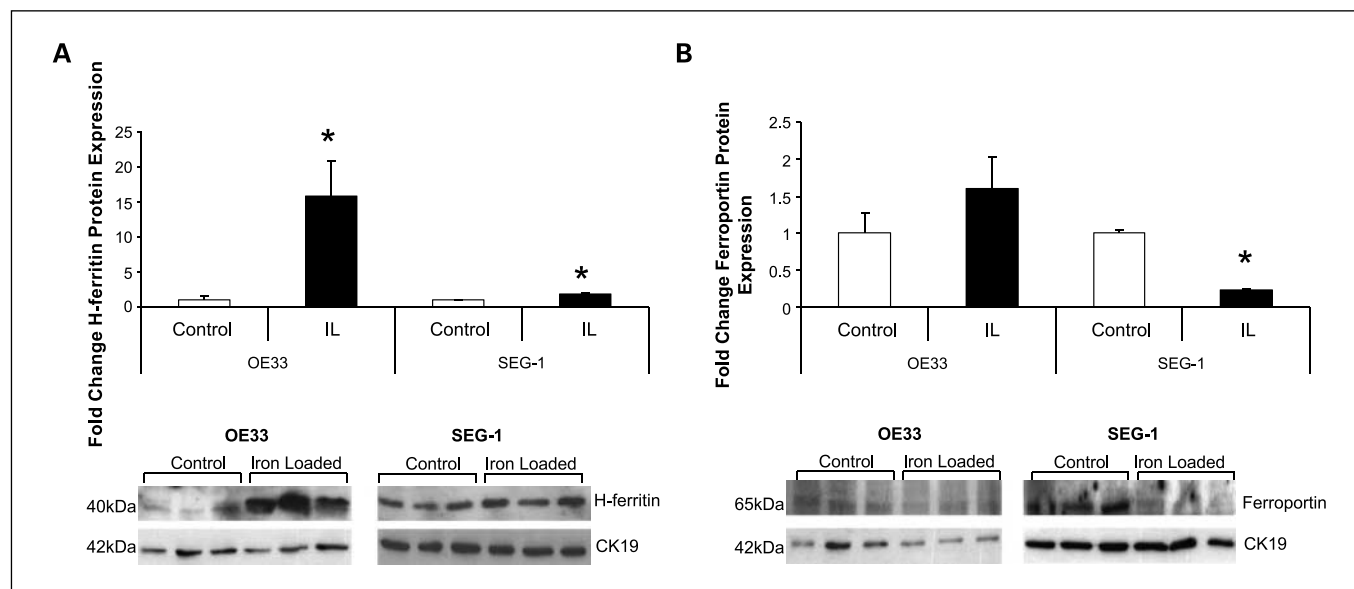


Fig. 6. Iron loading modulates ferroportin and H-ferritin protein expression. Extracts from control and 24-h iron-loaded OE33 and SEG-1 cells were subjected to Western blotting for H-ferritin (A) and ferroportin (B) analysis. Immunoreactive bands were quantitated by densitometry and controls normalized to 1.0. Cytokeratin 19 (*CK19*) was used for normalization. Columns, mean of three independent experiments; bars, SE. *, $P < 0.05$.

nodal metastasis. Whether changes in iron transport proteins can drive metastasis is unclear; however, it is possible that elevated intracellular iron caused by increased expression of iron import protein DMT1 mediates a repression in the cell adhesion molecule E-cadherin, a molecule that is commonly silenced in cellular invasion and metastasis. In support of this, we have previously shown iron-mediated E-cadherin repression in a colorectal model system (15).

We believe that it is highly unlikely that the overexpression of these iron transport proteins represents increased luminal iron uptake. Rather, we predict that their overexpression, coupled to their described localization, in adenocarcinoma suggests that the main route of iron acquisition is through transferrin receptor-mediated endocytosis. The only anomaly to this is DCYTB, which has no role in transferrin receptor-mediated endocytosis. We describe it to be cytoplasmic in localization, suggesting that neither is it involved in luminal iron uptake in adenocarcinoma. However, the fact that we observed DCYTB in the very basal layer of the stratified squamous esophagus suggests that it may have a function other than in iron absorption, such as cellular proliferation.

Thus, increased transferrin receptor-mediated endocytosis in the face of a potential functional loss of iron export, as suggested by cytoplasmic localization of ferroportin, might represent a mechanism by which iron could accumulate within esophageal epithelial cells. Indeed, we showed increased stainable iron and increased H-ferritin expression in tissue sections of Barrett's metaplasia and adenocarcinoma. If these adenocarcinoma cells are iron rich, one might predict reduced TfR1 and DMT1 expression because elevated iron will reduce the interaction of iron regulatory protein (IRP) with 3' IRE and consequently reduce mRNA stabilization (33, 34). However, we have observed paradoxical overexpression of TfR1 and DMT1 that suggests an aberration in the IRP/IRE system. Alternatively, these proteins may be modulated by other factors and that,

despite normal IRP/IRE iron sensing, the balance is skewed toward induced expression. One such factor could be c-MYC, an oncogene reported to induce TfR1 and IRP2, while repressing H-ferritin expression (31, 35). Interestingly, we previously showed c-MYC to be induced by acidified bile acids and overexpressed in the esophageal metaplasia-dysplasia-adenocarcinoma sequence (7). We compared the mRNA expression of *MYC* and *TfR1* in both Barrett's metaplasia and adenocarcinoma tissue and showed a positive correlation in adenocarcinoma but not in Barrett's metaplasia. This may suggest that in adenocarcinoma the balance is skewed toward MYC-mediated TfR1 induction rather than an IRE/IRP-mediated TfR1 repression.

Iron loading esophageal adenocarcinoma cell lines resulted in the predicted reduction in *TfR1* and *DMT1* mRNA and increase in H-ferritin protein expression. Iron loading SEG-1 cells also resulted in a significant reduction in ferroportin protein expression. Because *DMT1* has a 5' IRE, increasing cellular iron would be expected to result in increased ferroportin expression as reported in some cell types, such as macrophages (36). However, our data are consistent with other studies that suggest that iron does not regulate intestinal ferroportin expression in an IRE-predicted manner. This is exemplified by several studies showing elevated ferroportin expression in the duodenum of iron-deficient mice (25, 37).

Irrespective of the molecular mechanism by which adenocarcinoma cells become iron loaded, the cellular downstream effects are likely to be multiple. In this and previous studies, iron loading is important in cellular proliferation (15, 17, 27, 36). Historically, this has been attributed to iron being crucial in the activity of ribonucleotide reductase, an iron-containing enzyme responsible for the synthesis of deoxyribonucleotides (38). However, more recently, the phosphatase CDC14A, which has been shown to directly regulate the activity of several cell cycle proteins, is an IRE-containing protein

and thus regulated by iron (39). In addition, we have recently shown that iron can induce Wnt signaling, which culminates in oncogene activation and cellular proliferation (27). In support of a role for iron in proliferation, studies by Le and Richardson (40) have shown that reducing intracellular iron levels by chelation blocks cellular proliferation and induces differentiation through several cell cycle proteins, including NDRG1.

As well as modulating cellular proliferation, iron is likely to induce, through Fenton reaction chemistry, reactive oxygen species and oxidative stress (16). *In vitro* studies have clearly shown that iron can induce oxidative damage to DNA, protein, and lipid. Furthermore, murine models of esophageal adenocarcinoma suggest that iron-mediated oxidative stress in concert with reflux is central to esophageal carcinogenesis, as exemplified by marked overexpression of oxidative stress-responsive genes (9–12).

References

- Lagergren J. Adenocarcinoma of oesophagus: what exactly is the size of the problem and who is at risk? [review]. *Gut* 2005;54 Suppl 1:i1–5.
- Bollschweiler E, Wolfgarten E, Gutschow C, Holscher AH. Demographic variations in the rising incidence of esophageal adenocarcinoma in white males. *Cancer* 2001;92:549–55.
- Survival of cancer patients in Europe: The EURO-CARE II study. Lyon: IARC; 1999.
- Jankowski JA, Harrison RF, Perry I, Balkwill F, Tselepis C. Barrett's metaplasia. *Lancet* 2000;356:2079–85.
- Solaymani-Dodaran M, Logan RF, West J, Card T, Coupland C. Risk of oesophageal cancer in Barrett's oesophagus and gastro-oesophageal reflux. *Gut* 2004;53:1070–4.
- Hage M, Siersema PD, van Dekken H, Steyerberg EW, Dees J, Kuipers EJ. Oesophageal cancer incidence and mortality in patients with long-segment Barrett's oesophagus after a mean follow-up of 12.7 years. *Scand J Gastroenterol* 2004;39:1175–9.
- Tselepis C, Morris CD, Wakelin D, et al. Upregulation of the oncogene c-myc in Barrett's adenocarcinoma: induction of c-myc by acidified bile acid *in vitro*. *Gut* 2003;52:174–80.
- Koppert LB, Wijnhoven BP, van Dekken H, Tilanus HW, Dinjens WN. The molecular biology of esophageal adenocarcinoma [review]. *J Surg Oncol* 2005;92:169–90.
- Chen X, Yang CS. Esophageal adenocarcinoma: a review and perspectives on the mechanism of carcinogenesis and chemoprevention [review]. *Carcinogenesis* 2001;22:1119–29.
- Chen X, Ding YW, Yang G, Bondoc F, Lee MJ, Yang CS. Oxidative damage in an esophageal adenocarcinoma model with rats. *Carcinogenesis* 2000;21:257–63.
- Chen X, Yang G, Ding WY, Bondoc F, Curtis SK, Yang CS. An esophagogastrroduodenal anastomosis model for esophageal adenocarcinogenesis in rats and enhancement by iron overload. *Carcinogenesis* 1999;20:1801–8.
- Goldstein SR, Yang GY, Chen X, Curtis SK, Yang CS. Studies of iron deposits, inducible nitric oxide synthase and nitrotyrosine in a rat model for esophageal adenocarcinoma. *Carcinogenesis* 1998;19:1445–9.
- Hsing AW, McLaughlin JK, Olsen JH, Møller L, Wacholder S, Fraumeni JF, Jr. Cancer risk following primary hemochromatosis: a population-based cohort study in Denmark. *Int J Cancer* 1995;60:160–2.
- Lee DH, Anderson KE, Folsom AR, Jacobs DR, Jr. Heme iron, zinc and upper digestive tract cancer: the Iowa Women's Health Study. *Int J Cancer* 2005;117:643–7.
- Brookes MJ, Hughes S, Turner FE, et al. Modulation of iron transport proteins in human colorectal carcinogenesis. *Gut* 2006;55:1449–60.
- Huang X. Iron overload and its association with cancer risk in humans: evidence for iron as a carcinogenic metal [review]. *Mutat Res* 2003;533:153–71.
- Le NT, Richardson DR. The role of iron in cell cycle progression and the proliferation of neoplastic cells [review]. *Biochim Biophys Acta* 2002;1603:31–46.
- Bilello JP, Cable EE, Isom HC. Expression of E-cadherin and other paracellular junction genes is decreased in iron-loaded hepatocytes. *Am J Pathol* 2003;162:1323–38.
- McKie AT, Barrow D, Latunde-Dada GO, et al. An iron-regulated ferric reductase associated with the absorption of dietary iron. *Science* 2001;291:1755–9.
- Gruenheid S, Cellier M, Vidal S, Gros P. Identification and characterization of a second mouse Nramp gene. *Genomics* 1995;25:514–25.
- Gunshin H, Mackenzie B, Berger U, et al. Cloning and characterization of a mammalian proton-coupled metal-ion transporter. *Nature* 1997;388:482–8.
- Torti SV, Kwak EL, Miller SC, et al. The molecular cloning and characterization of murine ferritin heavy chain, a tumor necrosis factor-inducible gene. *J Biol Chem* 1988;263:12638–44.
- Frazer DM, Vulpe CD, McKie AT, et al. Cloning and gastrointestinal expression of rat hephaestin: relationship to other iron transport proteins. *Am J Physiol Gastrointest Liver Physiol* 2001;281:G931–9.
- Vulpe CD, Kuo YM, Murphy TL, et al. Hephaestin, a ceruloplasmin homologue implicated in intestinal iron transport, is defective in the sla mouse. *Nat Genet* 1999;21:195–9.
- McKie AT, Marciani P, Rolfs A, et al. A novel duodenal iron-regulated transporter, IREG1, implicated in the basolateral transfer of iron to the circulation. *Mol Cell* 2000;5:299–309.
- Aisen P. Transferrin receptor 1. *Int J Biochem Cell Biol* 2004;36:2137–43.
- Brookes MJ, Boulton J, Roberts K, et al. A role for iron in Wnt signalling. *Oncogene*. Epub ahead of print 2007 Aug 13.
- Martino E, Wild CP, Rotimi O, Darnton JS, Olliver RJ, Hardie LJ. IGFBP-3 and IGFBP-10 (CYR61) up-regulation during the development of Barrett's oesophagus and associated oesophageal adenocarcinoma: potential biomarkers of disease risk. *Biomarkers* 2006;11:547–61.
- Rockett JC, Larkin K, Darnton SJ, Morris AG, Matthews HR. Five newly established oesophageal carcinoma cell lines: phenotypic and immunological characterization. *Br J Cancer* 1997;75:258–63.
- Hughes SJ, Nambu Y, Soldes OS, et al. Fas/APO-1 (CD95) is not translocated to the cell membrane in esophageal adenocarcinoma. *Cancer Res* 1997;57:5571–8.
- O'Donnell KA, Yu D, Zeller KI, et al. Activation of transferrin receptor 1 by c-Myc enhances cellular proliferation and tumorigenesis. *Mol Cell Biol* 2006;26:2373–86.
- Altman DG. *Practical statistics for medical research*. New York: Chapman & Hall; 1991.
- Pantopoulos K. Iron metabolism and the IRE/IRP regulatory system: an update [review]. *Ann N Y Acad Sci* 2004;1012:1–13.
- Rouault TA. The role of iron regulatory proteins in mammalian iron homeostasis and disease [review]. *Nat Chem Biol* 2006;2:406–14.
- Wu KJ, Polack A, Dalla-Favera R. Coordinated regulation of iron-controlling genes, H-ferritin and IRP2, by c-MYC. *Science* 1999;283:676–9.
- Wang G, Miskimins R, Miskimins WK. Regulation of p27 (Kip1) by intracellular iron levels. *Biometals* 2004;17:15–24.
- Abboud S, Haile DJ. A novel mammalian iron-regulated protein involved in intracellular iron metabolism. *J Biol Chem* 2000;275:19906–12.
- Thelander L, Gräslund A, Thelander M. Continual presence of oxygen and iron are required for mammalian ribonucleotide reduction: possible regulation mechanism. *Biochem Biophys Res Commun* 1983;110:859–65.
- Sanchez M, Galy B, Dandekar T, et al. Iron regulation and the cell cycle: identification of an iron-responsive element in the 3'-untranslated region of human cell division cycle 14A mRNA by a refined microarray-based screening strategy. *J Biol Chem* 2006;281:22865–74.
- Le NT, Richardson DR. Iron chelators with high anti-proliferative activity up-regulate the expression of a growth inhibitory and metastasis suppressor gene: a link between iron metabolism and proliferation. *Blood* 2004;104:2967–75.